

Combination Anthelmintic Treatment for Persistent *Ancylostoma caninum* Ova Shedding in Greyhounds

Lindie B. Hess, BS, Laurie M. Millward, DVM, Adam Rudinsky DVM, Emily Vincent, BS, Antoinette Marsh, PhD

ABSTRACT

Ancylostoma caninum is a nematode of the canine gastrointestinal tract commonly referred to as hookworm. This study involved eight privately owned adult greyhounds presenting with persistent *A. caninum* ova shedding despite previous deworming treatments. The dogs received a combination treatment protocol comprising topical moxidectin, followed by pyrantel/febantel/praziquantel within 24 hr. At 7–10 days posttreatment, a fecal examination monitored for parasite ova. Dogs remained on the monthly combination treatment protocol until they ceased shedding detectable ova. The dogs then received only the monthly topical moxidectin maintenance treatment. The dogs remained in the study for 5–14 mo with periodical fecal examinations performed. During the study, three dogs reverted to positive fecal ova status, with two being associated with client noncompliance. Reinstitution of the combination treatment protocol resulted in no detectable ova. Use of monthly doses of combination pyrantel, febantel and moxidectin appears to be an effective treatment for nonresponsive or persistent *A. caninum* ova shedding. Follow-up fecal examinations were important for verifying the presence or absence of ova shedding despite the use of anthelmintic treatment. Limitations of the current study include small sample size, inclusion of only privately owned greyhounds, and client compliance with fecal collection and animal care. (*J Am Anim Hosp Assoc* 2019; 55:■■■–■■■. DOI 10.5326/JAAHA-MS-6904)

Introduction

Ancylostoma caninum is a nematode of the canine gastrointestinal (GI) tract commonly referred to as hookworm. Transmission of infective larvae occurs primarily by transmammary or skin penetration routes. Infection of dogs with *A. caninum* can cause anemia and diarrhea and may be associated with cutaneous larva migrans, a zoonotic condition associated with third-stage larvae in the environment. Patent hookworm infection diagnosis is made by fecal examination and finding the typical parasite ova ($63.92 \pm 5.28 \times 39.21 \pm 1.52 \mu\text{m}$, with an elliptical shape and smooth shell containing a cluster of cells referred to as a morula).¹ Several treatment options for treatment of dog gastrointestinal nematodes available

include the following: moxidectin^{a,b}, milbemycin oxime^c, fenbendazole^d, and/or pyrantel-containing products^{e,f}. Some products such as pyrantel only treat the adult stages of the parasite and are administered orally.² A unique feature of *A. caninum* is the ability of immature larval stages to migrate to and encyst in somatic tissues, either remaining there or eventually finding their way to the GI tract. During pregnancy, encysted larvae in somatic tissues reactivate and migrate to the mammary gland.³ These encysted or migrating larvae may also repopulate the GI tract.⁴ Drugs that are poorly absorbed from the GI tract (e.g., pyrantel) only target the adult stages and will not affect the encysted or migrating somatic larvae, making treatment of *A. caninum* difficult because it is prone to reactivation.

From the Department of Veterinary Preventive Medicine (L.B.H., A.M.), and Department of Veterinary Clinical Sciences (L.M.M., A.R., E.V.), College of Veterinary Medicine, The Ohio State University, Columbus, Ohio.

Correspondence: marsh.2061@osu.edu (A.M.)

EPG (eggs per gram); FEC (fecal egg count); GI (gastrointestinal)

The online version of this article (available at jaaha.org) contains supplementary data in the form of one table.

Accepted for publication: November 30, 2018.

Monitoring the efficacy of anthelmintic treatments is an important aspect of small animal practice. Veterinarians must ensure treatments are effective, manage client compliance with dispensed medications, and monitor for the possible development of drug-resistant nematodes. The frequency and extent of drug treatment failure in dogs in the United States is unknown because follow-up fecal analysis is not routinely performed after normal deworming procedures. Nematode drug resistance in ruminants and horses is well recognized as a clinically important problem.^{5,6} Drug-resistant nematodes are not thought to be as common in small animals. However, few studies are investigating drug resistance in gastrointestinal nematodes of dogs, and consequently, publications on this topic are limited. Pyrantel-resistant *A. caninum* has been described in Australia, and a drug-resistant *Dirofilaria immitis* strain has been reported in the United States.⁷⁻⁹ Recently, several cases of praziquantel-resistant *Dipylidium caninum*, a zoonotic cestode, were reported in the United States.¹⁰ These occurrences emphasize the importance of proper and effective deworming of dogs. Effective treatment is also an important public health measure because *A. caninum* is a zoonotic parasite.

Our study aimed to evaluate a combination anthelmintic therapy for dogs with persistent patent hookworm infection despite having used dewormers previously according to label instructions. We hypothesized that a combination of drugs with different mechanisms of action would eliminate *A. caninum* ova shedding in this group of greyhounds.

Materials and Methods

Dog Enrollment

Greyhounds were presented to The Ohio State University Veterinary Medical Center primarily through the volunteer blood bank program and were screened for *A. caninum* ova by fecal analysis using a double centrifugation technique.¹¹ Dogs >2 yr of age were enrolled in the study based on two sequential positive fecal examinations for hookworm ova despite having used a pyrantel pamoate^f treatment provided in a monthly dosing formulation.

To confirm the identification of *A. caninum*, both morphological and DNA analyses were performed. Length and width measurements of 3–5 ova per fecal sample were made at 100× using a calibrated light microscope and compared with reference values for ova of *A. caninum* (reference values, $63.92 \pm 5.28 \times 39.21 \pm 1.52 \mu\text{m}$).¹ For DNA analysis, purified eggs or larvae from coprocultures from each dog were harvested and pelleted, and DNA was extracted following the manufacturer's protocol^g. This procedure was followed by polymerase chain reaction–restriction-length polymorphism analysis using polymerase chain reaction and DNA fragment analysis to confirm *A. caninum* ova from all dogs.¹ In

addition, amplified DNA from Dog 8 underwent DNA sequencing to compare with published *A. caninum* genetic data. Positive control DNA of *A. caninum* and *Ancylostoma braziliense* were kindly provided by Janice L. Liotta (College of Veterinary Medicine, Cornell University).

All dogs included in the study were client-owned and managed. Volunteer blood donor dogs were examined and provided routine care to ensure they were healthy and free of transmissible infectious diseases. These dogs were also treated for both endo- and ectoparasites, and parasite control therapy was selected based upon discussion involving the veterinarian, blood bank staff, and the client. For this study, the owners provided a separate informed consent document for their dogs to participate. Clients were advised to leash walk dogs and clean up all feces immediately after defecation to prevent reinfection by *A. caninum*. The owners were responsible for administering the provided anthelmintic and ectoparasite preventive (Flumethrin/Imidacloprid^h or Fipronil/(s)-methopreneⁱ). Actual owner compliance related to these aspects was unknown unless the owner self-reported noncompliance.

Treatment and Monitoring Fecal Hookworm Ova

Once enrolled in the study, fecal samples were collected according to the study design (Figure 1). A Modified Stoll's test was performed to obtain an initial fecal egg count (FEC) for each dog.¹¹ The monthly anthelmintic treatment and repeat fecal examination protocol followed the study design (Figure 1). Figure 2 is a summary showing each dog, the fecal ova monitoring, and the duration of the three anthelmintic treatments used in this study.

This study had three phases. In the first phase, all dogs were placed on an initial variable treatment. Because of the lack of success in preventing ova shedding in any of the enrolled dogs, a second phase was implemented, the combination treatment protocol, for all of the dogs. Finally, once ova shedding ceased, the third phase, the maintenance treatment, was initiated in the participating dogs.

Details of the study treatments, particularly the initial variable treatment, are provided in Supplementary Table I. The variable treatment included a single monthly dosage based on body weight of milbemycin oxime/lufenuron, febantel/praziquantel/pyrantel, ivermectin/pyrantel, or moxidectin/imidacloprid. The attending veterinarian, owner, and blood bank staff discussed and determined the anthelmintic drugs to administer to the dogs during the variable treatment period. Once treatment was started, a posttreatment fecal sample (7–10 days later) was evaluated for parasite ova.¹²⁻¹⁴ During the initial variable treatment period (1–3 mo), all dogs remained positive. The dogs were then placed on the combination protocol treatment consisting of topical moxidectin (2.5–4.0 mg/kg) with oral pyrantel pamoate (5.23–8.64 mg/kg), praziquantel (5.23–8.64

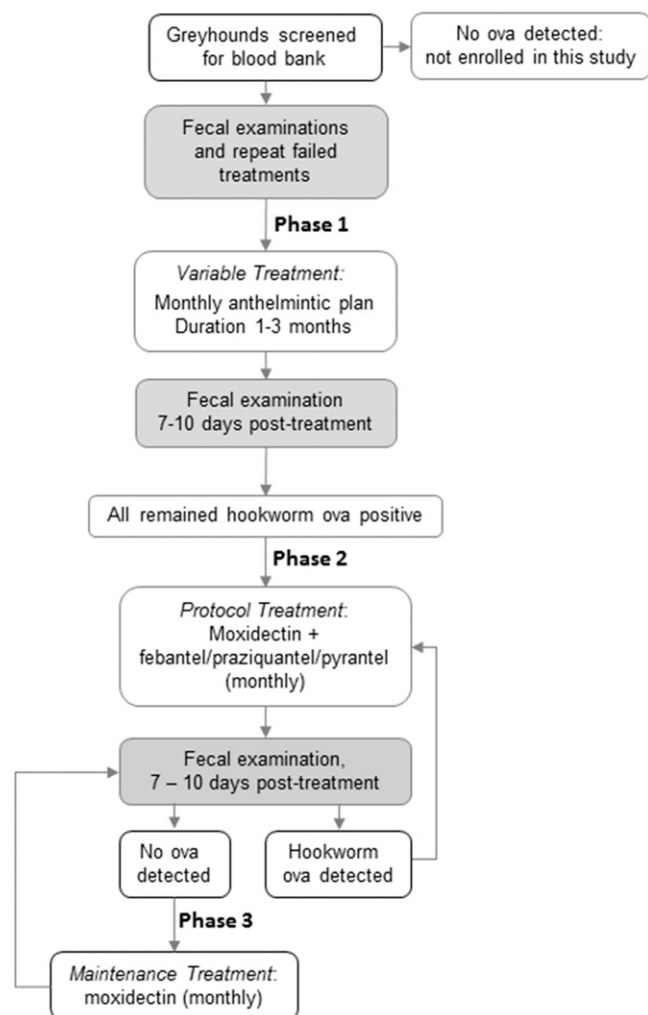


FIGURE 1 Study flow diagram showing screening, enrollment, and progression of treatment and fecal ova monitoring. Dogs were initially started with the variable treatment, then protocol treatment, and finally maintenance treatment. All drugs were provided in the label dose according to the individual dog's weight.

mg/kg), and febantel (26.17–43.24 mg/kg) given within a 24 hr period. The dogs who remained positive for ova after the combination treatment protocol received another combination treatment protocol at the start of the next month (Figure 1). If negative after the combination treatment protocol, the dog received a dose of topical moxidectin (2.5–4.0 mg/kg; maintenance treatment) for application at the start of the next month for GI parasite, heartworm, and flea prevention (Figure 1). In each dog, whether on the variable or maintenance treatments, a post-treatment fecal sample (7–10 days) was evaluated to detect any ova, and the Modified Stoll's procedure was used to quantify the number of eggs per gram (EPG) of feces. The dogs were followed for a period of 5–14 mo (Figure 2). For Dogs 2–5, when on the

maintenance treatment, the owners did not consistently provide fecal samples once the dogs stopped shedding ova and achieved multiple “no ova detected” laboratory results. For Dogs 7 and 8, the owners elected not to continue with the study when the dogs achieved a single “no ova detected” laboratory result.

Results

Eight greyhounds (Dogs 1–8), all retired from racing, between the ages of 2 and 5 yr were included in the study. The history of six of the eight dogs (Dogs 1–6) included potentially persistent *A. caninum* patent infection that delayed their active participation in the blood bank. We defined persistent patent infection as detection of hookworm ova for ≥ 6 mo with a history of appropriate anthelmintic treatment. Two dogs (Dogs 7 and 8) were recently retired from a greyhound racing track within 1 mo of their screening for potential blood bank enrollment. Because of their recent retirement, medical history, including specific information on prior parasitic infections (including persistent hookworm infection) and treatment, was limited. Dogs 7 and 8 were positive for hookworms at initial blood bank screening. Both dogs had at least 2 sequential mo of positive fecal hookworm ova detection and were classified as persistent shedders. Dog 4 presented with clinical signs of diarrhea and thin hair coat. All other dogs (Dogs 1–3 and 5–8) in the study were subclinical, despite positive fecal samples. Using the international greyhound database, www.greyhound-data.com, each dog was traced back to its dam and the dam litter number (Figure 2).

A summary of the duration for three (variable, protocol, or maintenance) treatment periods are shown in Figure 2. The study and treatment period duration varied for each dog, but eventually, all eight dogs stopped shedding detectable ova, resulting in a 100% reduction in ova shedding. It took 1–4 consecutive mo of the protocol treatment, topical moxidectin^a followed within 24 hr by an oral dose of the pyrantel, praziquantel, and febantel combination product^c, for the dogs to cease shedding ova in their feces. Of the eight dogs who achieved a no ova detection fecal examination, five of them remained negative during the study and using a monthly dose of topical moxidectin. Three dogs (Dogs 3, 4, and 7) reverted to shedding *A. caninum* in their feces while on the monthly moxidectin maintenance treatment. Reinstitution of the combination treatment protocol including pyrantel and febantel in addition to moxidectin with a subsequent fecal analysis after 7–10 days resulted in no ova being detected. Two dogs achieving no ova detection were lost from the study at 5 and 6 mo, which was attributed to lack of owner interest in providing the necessary samples.

The parasite ova for all dogs were *A. caninum* based on morphology and DNA analysis, including DNA sequencing for ova

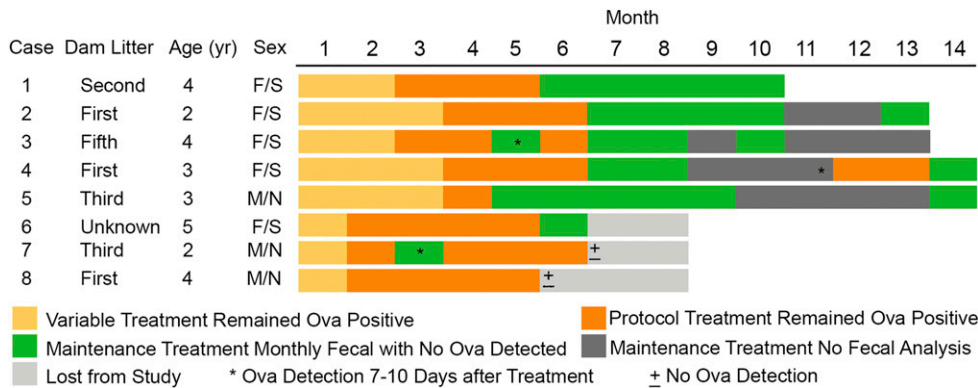


FIGURE 2 Summary of cases, parasite treatments, and *Ancylostoma caninum* ova detection after sequential monthly treatments using the variable, protocol, and maintenance treatments.

obtained from Dog 8. *A. braziliense* DNA was not detected in the fecal samples in any of the eight dogs.

Discussion

We were successful in clearing persistent *A. caninum* ova shedding using a regimen consisting of a combination of two commercial products, topical moxidectin^a and an oral formulation of pyrantel, praziquantel, and febantel^c. Six of the eight dogs (75%) stopped shedding hookworm ova after ≤3 mo using this regimen. The other two dogs (Dogs 7 and 8, the two dogs most recently retired from racing) required 5 mo of treatment using the regimen. Overall, all eight dogs (100%) stopped shedding hookworm ova within 3–5 mo of using the monthly treatment, which included the combination of two different commercially packaged anthelmintics at the label dose. The product labels contain no contraindication for the use of these products together within a 24 hr period, and thus, the treatment protocol regimen remained in compliance with product labeling.

Three of the eight dogs (Dogs 3, 4, and 7) who stopped shedding hookworm ova experienced reoccurrence of patent *A. caninum* shedding while on the maintenance treatment. Because of reoccurrence of hookworm ova shedding, the dogs received the monthly dosage of moxidectin followed by the oral pyrantel, praziquantel, and febantel combination product within 24 hr. Again, fecal samples were monitored 7–10 days posttreatment. Once the dogs ceased ova shedding, they received only the monthly topical moxidectin and were monitored monthly for the presence of ova. All three of these dogs stopped shedding ova after implementation of the combination treatment protocol again.

Based on client communications, reoccurrence of *A. caninum* in Dogs 3 and 7 likely was associated with failure of owner compliance, resulting in a greater duration (>30 days and <45 days) between anthelmintic treatments. Additionally, reoccurrence in Dog 3 could have been due to reinfection from viable environmental larvae. After one additional course of the combination treatment protocol, Dog 3 stopped shedding detectable ova and remained on the monthly

moxidectin dosing with no ova detected during the subsequent months of monitoring. A decrease in steady state concentrations of moxidectin between treatments could have been a contributing factor. Steady state concentrations of moxidectin are reported to be effective for up to 28 days after treatment.¹⁵ Therefore, if clients do not comply with the recommended monthly dosing requirement and a decrease in systemic concentration occurs after day 28, tissue-sequestered larvae may migrate and establish a patent GI infection. Such a situation may have occurred in Dog 4. An alternative, but undocumented and less likely, potential reason for the reoccurrence of ova shedding is the possibility that combination treatment decreased ova production by fertile female worms to an undetectable level. It is possible then that when moxidectin alone was implemented, ova shedding was resumed by female worms that were already present.

Although not evaluated in our study, the use of antigen detection or video capsule endoscopy after anthelmintic treatment could supplement fecal monitoring to confirm the adulticidal activity of the dewormer, particularly in the dogs experiencing reoccurrence of ova shedding.^{16,17} If adult worms remain after anthelmintic treatment, it could suggest drug-resistant *A. caninum* or potentially decreased worm fecundity immediately after using the protocol treatment. If 10–12 days after anthelmintic treatment no antigen is present and no adult worms are visualized by endoscopy, then the ova shedding observed later in treated dogs (≥2 wk posttreatment) would suggest that patent hookworm infection resulted from reactivation of tissue larvae or larvae from the environment.

Dogs 6–8 stopped shedding ova after a longer course of the combination treatment protocol as compared with the other dogs. Dog 6 had an initial FEC of 3155 EPG, which was higher than the counts of the other dogs, which ranged from 10 to 650 EPG at enrollment. This higher EPG suggests a larger worm burden as well as a greater number of arrested larvae in the tissues, thereby explaining why a longer period of treatment to remove adult females and prevent ova shedding was observed. When the adult worms

were removed by deworming, it is possible the GI tract was repopulated by a potential large tissue reservoir of arrested larvae. Dog 8 also started with a relatively higher FEC of 650 EPG as compared with the other study dogs. Dog 8 was retired from racing only 1 mo before evaluation for enrollment in the volunteer blood bank. At the time of initial enrollment, Dog 8 had surgery and received medical management for a complex left tarsal fracture. During this time, the dog was treated for a small intestinal foreign body, displayed signs of separation anxiety, experienced pica, and was infected with *Eucoleus* sp., another nematode parasite. Stress can be associated with immune suppression, and these events suggest that Dog 8 experienced stress and associated immunosuppression that may have contributed to protracted patent hookworm infection.¹⁸ Although stress-induced immunosuppression is thought to play a role in recrudescence of patent infection, experimentally infected dogs given prednisolone did not release significantly more hypobiotic (arrested) larvae in comparison with untreated controls.⁴ Alternatively, Dog 8 may have had a large pool of dormant somatic tissue larvae reactivating and migrating to the GI tract. Natural infection, nonterminal studies limit our conclusions regarding adult worm burdens, hypobiotic larvae reactivation, and ultimately the effectiveness of treatment. In contrast, experimental trials with purpose-bred dogs allow for prestudy monitoring for somatic tissue larvae reactivation, known dosage, and timing of infective larvae to compare infected dewormed dogs with nontreated infected control dogs. The study dogs' originating litter numbers varied from a dam's first litter to at least the fifth litter from the dog's corresponding dam.

The combination of topical moxidectin and oral combination of pyrantel, praziquantel, and febantel was chosen for our study because they are anthelmintic drugs currently on the market that are readily available to clinicians. These drugs have different mechanisms of action.² Moxidectin's mechanism of action is to interfere with the function of gamma-aminobutyric acid and glutamate-gated chloride channels of nematodes, causing flaccid paralysis and death of susceptible parasites.¹⁹ Moxidectin also can reach steady state concentrations in tissues and blood, which may make it useful in preventing migrating reactivated hookworm larvae from reaching or maturing in the GI tract to establish patency. It may take three to four monthly doses of commercially available moxidectin to reach the steady state concentrations in tissues reported to be effective against *A. caninum*.¹⁵ The moxidectin label claims effectiveness against fourth-stage larvae, immature adults, and adults. Our results also suggest that moxidectin does not affect encysted, non-metabolically active larvae. Dog 4 reinitiated ova shedding during early April. The owner reported hand walking the dog. During the northeast US winters, the outdoor temperatures would not be conducive to environmental survival of *A. caninum* larvae or

transmission within the preceding month, as the outdoor temperatures range from an average low of 0°C to an average high of 11°C in Ohio. The optimum temperature for free-living development of *Ancylostoma* is 30°C.^{20,21} Therefore, the patent infection of Dog 4 during month 11 most likely resulted from activation of encysted larvae or adult females' resumption of shedding detectable ova. Pyrantel acts at the nicotinic cholinergic receptors of the nematode, leading to persistent depolarization and spastic paralysis of the worm.²² Pyrantel is primarily confined to the GI tract and is not readily absorbed into the blood or somatic tissues. Febantel, a probenzimidazole, is readily metabolized to fenbendazole in the dog. It affects tubulin polymerization in the nematode and causes paralysis and death of the parasite.² The dosage of praziquantel in the combination dewormer tablet used in this study is for tapeworm control, and its ability to interrupt the hookworm life cycle in the dog has not been described.

Uncertain reliability of client compliance was a limitation of our study. The owner of Dog 1 was opposed to the use of topical moxidectin, and therefore, treatment with moxidectin, in combination with pyrantel and febantel, was delayed by 3 mo. During this time, the dog continued to shed hookworm ova despite using the label dose of milbemycin oxime^c in combination with the pyrantel and febantel within 24 hr. However, after learning of the positive impact of the regimen of moxidectin with pyrantel and febantel, the owner of Dog 1 agreed to use the combination treatment protocol. In this case, the dog stopped shedding ova within 2 mo of using moxidectin with pyrantel and febantel. In Dog 7, after the dog stopped shedding ova, the owner continued with the moxidectin but delayed administering the moxidectin so the dosing interval was extended to ~45 days rather than 1 mo. This delay in dosing was then followed by a positive fecal examination. When the protocol treatment was reinstated, both Dogs 2 and 7 stopped shedding ova after 3 consecutive mo of following the specified dosing interval. These results emphasize that timing of dosing and anthelmintic use play an important role in preventing patent *A. caninum* infection.

Another limitation of our study was the small sample size. A larger sample size would have provided greater confidence in our findings. We were limited by the number of dogs undergoing pre-blood screening and willing owners to comply with the study requirements. Also, we were unable to obtain support for analysis of drugs or metabolites, which would have been useful in ensuring our results were associated with specific drug levels associated with treatment success. In addition, although moxidectin is described as a two-compartment model in beagles, this model may not adequately describe moxidectin's behavior in greyhounds.²³ Moxidectin is reported to have a low clearance and high volume of distribution, resulting in a longer half-life of the active compound.²³ Moxidectin

is a lipophilic drug with wide tissue distribution, and as a result of its lipophilic nature, the drug is likely to be deposited in adipose tissue, affecting its volume of distribution.²³ Greyhounds are known to have more lean body mass and therefore may eliminate moxidectin differently than other breeds.

An attractive hypothesis is that the moxidectin, once reaching a steady state level and given every 30 days, may continuously “mop up” spontaneously reactivating larvae that make it to the fourth stage or even early adults not quite patent. Dogs reaching this steady state drug level would then have potential protection against developing a patent infection. Recommending year-round administration of the moxidectin-based dewormer would not only provide *D. immitis* prevention but also prevent or assist with *A. caninum* ova shedding.

Our study population only included greyhounds. Greyhounds are frequently used in The Ohio State University Veterinary Medical Center volunteer blood bank because they are large dogs and can provide a relatively large donation volume. In addition, many greyhounds are negative for several dog erythrocyte antigens except for dog erythrocyte antigen 4, which makes such greyhounds universal donors.²⁴ Furthermore, no published studies are available on the pharmacokinetics of moxidectin in greyhounds. However, the effects of moxidectin in relation to different body compositions and breeds are reported in pigs and cattle.^{25,26} In pigs with a lower amount of back fat, moxidectin is distributed more rapidly.²⁵ Greyhounds are lean animals with less adipose tissue than other breeds of dogs. Therefore, based on the pig model, moxidectin may distribute faster in lean greyhounds than in other dog breeds such as the beagle. Greyhounds have markedly different responses to anesthetic, analgesic, and antimicrobial drugs.^{27–29} Another product contains a time-release formulation of moxidectin^b and is labeled for a 6 mo protective period for GI nematodes and heartworm prevention. We did not evaluate this formulation of moxidectin because we wanted to ensure that monthly fecal examinations occurred concurrently with dispensing the drug products we were evaluating. Once dogs achieved a no ova detected result, owner compliance was a concern for completion of all the study requirements as the owner was less inclined to comply with the required fecal sample submission portion of the study.

Conclusion

The combination of topical moxidectin and an oral combination of pyrantel, febantel, and tapeworm dewormer, praziquantel, is a reasonable treatment option when a dog presents with a chronic patent *A. caninum* infection that has failed to respond to a single commercially formulated anthelmintic. Our treatment regimen could be beneficial for greyhounds, a breed that tends to have more

persistent patent infections with helminth parasites, as reported in British racing greyhounds.³⁰ Our study also emphasizes the importance of routine fecal examination after the administration of an anthelmintic. Follow-up fecal examinations ensure that treatments are effective and that ongoing patent infections with GI nematodes, such as *A. caninum*, do not continue to pose a risk to the dog or the owner by environmental contamination with viable ova. ■

This project was supported by The Ohio State University, College of Veterinary Medicine, Department of Veterinary Preventive Medicine and the NIH T35 Training Grant 5T35OD010977-09.

FOOTNOTES

- ^a Advantage Multi; Bayer, Shawnee Mission, Kansas
- ^b Proheart 6; Zoetis, Parsippany, New Jersey
- ^c Sentinel Spectrum; Virbac, Fort Worth, Texas
- ^d Panacur; Merck Animal Health, Intervet, Madison, New Jersey
- ^e Drontal Plus; Bayer, Shawnee Mission, Kansas
- ^f Heartgard Plus; Boehringer Ingelheim, Merial Inc., Duluth, Georgia
- ^g Qiagen DNAeasy Blood and Tissue Kit; Qiagen Sciences, Germantown, Maryland
- ^h Seresto; Bayer, Shawnee Mission, Kansas
- ⁱ Frontline Plus; Boehringer Ingelheim, Merial Inc., Duluth, Georgia

REFERENCES

1. Lucio-Forster A, Liotta J, Yaros J, et al. Morphological differentiation of eggs of *Ancylostoma caninum*, *Ancylostoma tubaeforme*, and *Ancylostoma braziliense* from dogs and cats in the United States. *J Parasit* 2012;98(5):1041–44.
2. Conder GA. Chemical control of animal parasitic nematodes. In: D.L. Lee, ed. *The Biology of Nematodes*. 1st ed. London: Taylor & Francis; 2002:521–9.
3. Anderson RC. The superfamily ancylostomatoidea. In: *Nematode Parasites of Vertebrates: Their Development and Transmission*. 1st ed. Oxon (United Kingdom): CABI Publishing; 1992:45–6.
4. Schad GA, Page MR. *Ancylostoma caninum*: adult worm removal, corticosteroid treatment, and resumed development of arrested larvae in dogs. *Exp Parasitol* 1982;54(2):303–9.
5. Coles GC, Jackson F, Pomroy WE, et al. The detection of anthelmintic resistance in nematodes of veterinary importance. *Vet Parasitol* 2006; 136(3–4):167–85.
6. Kaplan RM. Anthelmintic resistance in nematodes of horses. *Vet Res* 2002;33(5):491–507.
7. Kopp SR, Coleman GT, Mccarthy JS, et al. Application of in vitro anthelmintic sensitivity assays to canine parasitology: detecting resistance to pyrantel in *Ancylostoma caninum*. *Vet Parasitol* 2008;152(3–4):284–93.
8. Kopp SR, Kotze AC, McCarthy JS, et al. High-level pyrantel resistance in the hookworm *Ancylostoma caninum*. *Vet Parasitol* 2007;143(3–4):299–304.
9. Bourguinat C, Lee AC, Lizundia R, et al. Macrocytic lactone resistance in *Dirofilaria immitis*: Failure of heartworm preventives and investigation of genetic markers for resistance. *Vet Parasitol* 2015;210(3–4):167–78.
10. Chelladurai JJ, Kifleyohannes T, Scott J, et al. Praziquantel resistance in the zoonotic cestode *Dipylidium caninum*. *Am J Trop Med Hyg* 2018; 99(5):1201–5.
11. Zajac AM, Conboy GA. Fecal examination for the diagnosis of parasitism. In: *Veterinary Clinical Parasitology*. 8th ed. Chichester (United Kingdom): Wiley-Blackwell, 2012;4–12.

12. Boillat CS, Gaschen FP, Hosgood GL. Assessment of the relationship between body weight and gastrointestinal transit times measured by use of a wireless motility capsule system in dogs. *Am J Vet Res* 2010;71(8): 898–902.
13. Reynoldson JA, Behnke JM, Pallant LJ, et al. Failure of pyrantel in treatment of human hookworm infections (*Ancylostoma duodenale*) in the Kimberley region of north west Australia. *Acta Trop* 1997; 68(3):301–12.
14. Obiukwu MO, Onyali IO. Comparative efficacy of ancylosol, ivermectin, mebendazole and piperazine against *Ancylostoma caninum* in experimentally infected pups. *Animal Res Int* 2006;3(3)540–4.
15. Bowman DD, Grazette AR, Basel C, et al. Protection of dogs against canine heartworm infection 28 days after four monthly treatments with Advantage Multi® for dogs. *Parasit Vectors* 2016;9:12–9.
16. Elsemore DA, Geng J, Cote J, et al. Enzyme-linked immunosorbent assays for coproantigen detection of *Ancylostoma caninum* and *Toxocara canis* in dogs and *Toxocara cati* in cats. *J Vet Diagn Invest* 2017;29(5):645–53.
17. Lee ACY, Epe C, Simpson KW et al. Utility of capsule endoscopy for evaluating anthelmintic efficacy in fully conscious dogs. *Int J Parasitol* 2011;41(13–14):1377–83.
18. Dohms JE, Metz A. Stress-mechanisms of immunosuppression. *Vet Immunol Immunopathol* 1991;30(1):89–109.
19. Cobb R, Boeckh A. Moxidectin: a review of chemistry, pharmacokinetics and use in horses. *Parasit Vectors* 2009;2(Suppl 2):S5–S13.
20. Hill RL Jr, Roberson EL. Temperature-induced separation of larvae of *Uncinaria stenocephala* from a mixed fecal culture containing *Ancylostoma caninum*. *J Parasitol* 1985;71(3):390–1.
21. Kalkofen UP. Hookworms of dogs and cats. *Vet Clin North Am Small Anim Pract* 1987;17(6):1341–54.
22. Martin RJ. Modes of action of anthelmintic drugs. *Vet J* 1997;154(1):11–34.
23. Vanapalli SR, Hung YP, Fleckenstein L, et al. Pharmacokinetics and dose proportionality of oral moxidectin in beagle dogs. *Biopharm Drug Dispos* 2002;23(7):263–72.
24. Iazbik C, O'Donnell M, Marin L et al. Prevalence of dog erythrocyte antigens in retired racing Greyhounds. *Vet Clin Path* 2010;39(4):433–5.
25. Craven J, Bjørn H, Hennessy D, et al. Pharmacokinetics of moxidectin and ivermectin following intravenous injection in pigs with different body compositions. *J Vet Pharmacol Ther* 2001;24(2):99–104.
26. Sallovitz J, Lifschitz A, Imperiale F, et al. Breed differences on the plasma availability of moxidectin administered pour-on to calves. *Vet J* 2002;164(1):47–53.
27. Court MH. Anesthesia of the sighthound. *Clin Tech Small Anim Pract* 1999;14(1):38–43.
28. KuKanich B, Coetzee JF. Comparative pharmacokinetics of amikacin in greyhound and beagle dogs. *J Vet Pharmacol Ther* 2008;31(2):102–7.
29. KuKanich B, Borum, S. The disposition and behavioral effects of methadone in greyhounds. *Vet Anaesth Analg* 2008;35(3):242–8.
30. Jacobs DE, Prole JH. Helminth infections of British dogs: Prevalence in racing greyhounds. *Vet Parasitol* 1976;1(4):377–87.