

# What Is Your Diagnosis?

In cooperation with

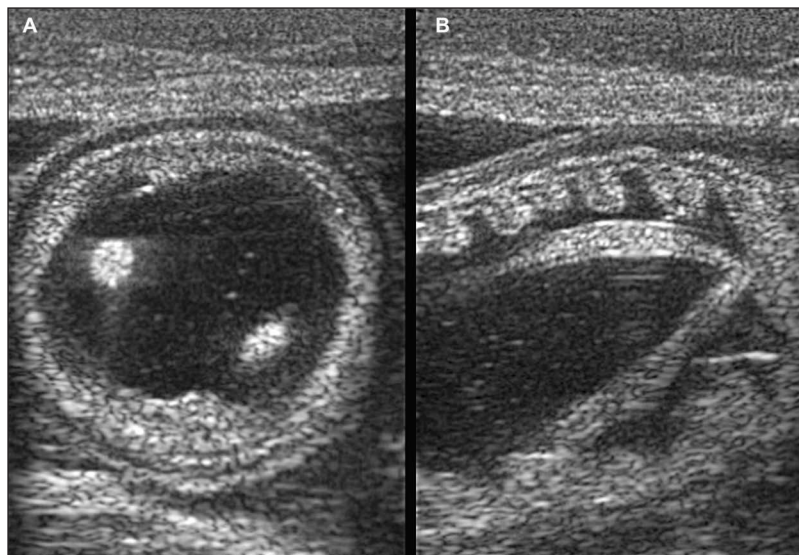


Figure 1—Ultrasonographic cross-sectional (A) and longitudinal (B) views of a loop of small intestine obtained by transcutaneous imaging of the ventral aspect of the abdomen of a 3-month-old Thoroughbred foal evaluated because of acute signs of abdominal distention.

## History

A 3-month-old Thoroughbred filly weighing 225 kg (495 lb) was evaluated at the Ontario Veterinary College Teaching Hospital for acute respiratory distress and suspected pneumonia. On the morning of the evaluation, the foal was bright and alert and was observed grazing in the field. Late in the afternoon, the foal was found in lateral recumbency. The foal had signs of depression, was anorexic and tachypneic, and had increased intensity of lung sounds; the buccal mucous membranes were cyanotic. No treatment was given prior to referral. The foal had been administered an anthelmintic (an ivermectin product) at the labeled dose of 0.2 mg/kg (0.09 mg/lb) the previous day.

On evaluation, the foal was in lateral recumbency, had signs of depression, and was reluctant to rise. On physical examination, the foal was tachypneic (88 breaths/min) and tachycardic (140 beats/min) and was clinically assessed to be severely dehydrated (> 10% fluid loss). The ventral aspect of the abdomen was bilaterally distended. Venous blood-gas analysis revealed severe acidosis (pH, 7.10; reference range, 7.35 to 7.45). Markedly high PCV (70%; reference range, 28% to 47%) and high-normal total solids concentration (70 g/L; reference range, 56 to 75 g/L) were also present. Transcutaneous ultrasonography of the ventral aspect of the abdomen was performed (Figure 1).

**Determine whether additional imaging studies are required, or make your diagnosis from Figure 1—then turn the page →**

---

This report was submitted by Luis G. Arroyo, DVM, PhD; Rolando J. Quesada, DVM; Carlos E. Medina-Torres, DVM, DVSc; and John D. Baird, BVSc, PhD; from the Department of Clinical Studies, Ontario Veterinary College, University of Guelph, Guelph, ON N1G 2W1, Canada. Dr. Medina-Torres' present address is Australian Equine Laminitis Research Unit, School of Veterinary Science, University of Queensland, Gatton, QLD 4343, Australia. Dr. Quesada's present address is Department of Small Animal Clinical Sciences, College of Veterinary Medicine, University of Florida, Gainesville, FL 32610.

Address correspondence to Dr. Arroyo (larroyo@uoguelph.ca).

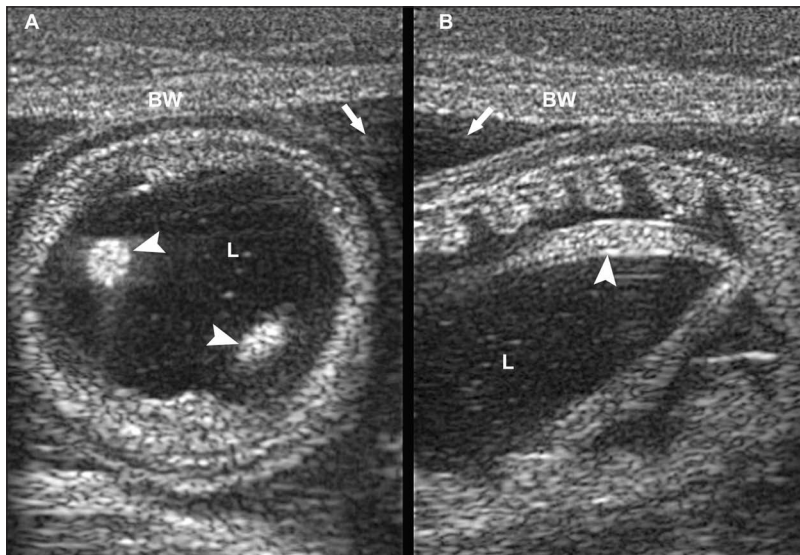


Figure 2—Same ultrasonographic images as in Figure 1. A—Cross-sectional image of a loop of small intestine revealing marked fluid accumulation within the lumen (L) and 2 hyperechoic structures (arrowheads), which were observed moving during the ultrasonographic examination. B—Longitudinal section of the loop of small intestine also revealing marked intraluminal fluid content (L) and a longitudinal section of an adult ascarid (arrowhead). On both images, also notice the severely thickened small intestinal wall and echogenic peritoneal fluid (arrow). BW = Body wall.

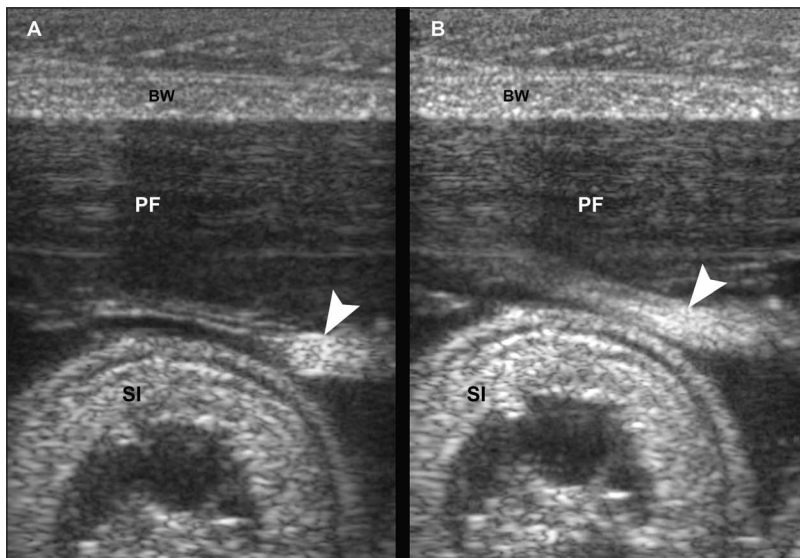


Figure 3—Similar ultrasonographic images of the abdomen of the horse in Figure 1. A—Cross-sectional image of a hyperechoic ascarid (arrowhead) within the abdominal cavity (which was observed moving during the ultrasonographic examination) next to a loop of small intestine (SI). A large amount of echogenic peritoneal fluid (PF) is visible in the background. B—Longitudinal image of a hyperechoic structure (arrowhead) in the abdominal cavity next to a cross-sectional image of a loop of small intestine (SI). Notice the echogenic free peritoneal contents (PF) and longitudinal section of an ascarid (arrowhead). Subjectively, the small intestinal wall appears severely thickened (A and B).

### Diagnostic Imaging Findings and Interpretation

Transcutaneous abdominal ultrasonography revealed large amounts of echogenic free fluid in the abdominal cavity and distended loops of small intestine with a markedly thickened wall (Figure 2). Hyperechoic, round, long, no-shadowing, fast-moving structures were observed mostly within the lumen of the small intestine but also within the abdominal cavity (Figure 3).

A nasogastric tube was passed and a copious amount of reflux containing adult ascarids was obtained. Collec-

tively, these findings were consistent with peritonitis, likely the result of intestinal rupture secondary to roundworm (*Parascaris equorum*) impaction. The foal was euthanized, and a postmortem examination revealed an intestinal perforation along the mesenteric border of the distal portion of the jejunum. There was a large amount of serosanguineous fluid containing feed material, fibrin, and adult ascarids in the abdominal cavity.

### Comments

Small intestinal obstructions occur spontaneously in young horses with large burdens of *P equorum*.<sup>1</sup> Ultrasonographically, roundworms appear as single or multiple, echogenic, no-shadowing, linear, motile, curved strips or rods with or without echoic tubular central lines, and on transverse section, they appear as hyperechoic round structures.<sup>2</sup> Ultrasonography is widely used to diagnose ascarid infection in humans (especially in endemic areas) and can be a quick, noninvasive, inexpensive tool for diagnosing the presence of ascarids in horses as described in this report. Furthermore, the observation of free ascarids in the small intestine lumen and peritoneal cavity, combined with the large amount of echogenic abdominal effusion, was consistent with gastrointestinal rupture. Therefore, ultrasonography was useful in the diagnosis of intestinal perforation, most likely due to an obstruction caused by ascarids. At our hospital, ascarid infections have been recognized in several affected horses initially through the use of ultrasonographic examinations prior to definitive diagnosis at endoscopy or surgery.

Ascarid impactions can be treated medically, but most will require surgical intervention. The prognosis for short-term survival is fair but for long-term survival (> 1 year after surgery) is guarded.<sup>3</sup> Preventative measures against infection with *P equorum* remain of paramount importance, particularly in light of the development of ivermectin resistance in *P equorum*.<sup>4</sup> Fecal monitoring for anthelmintic efficacy should be an integral component of environment management and the anthelmintic treatment program in foals.

1. Southwood LL, Ragle CA, Snyder JR, et al. Surgical treatment of ascarid impactions in horses and foals, in *Proceedings*. 42nd Annu Conv Am Assoc Equine Pract 1996;258–261.
2. Mahmood T, Mansoor N, Quraishy S, et al. Ultrasonographic appearance of *Ascaris lumbricoides* in the small bowel. *J Ultrasound Med* 2001;20:269–274.
3. Cribb NC, Coté NM, Bouré LP, et al. Acute small intestinal obstruction associated with *Parascaris equorum* infection in young horses: 25 cases (1985–2004). *N Z Vet J* 2006;54:338–343.
4. Hearn FPD, Peregrine AS. Identification of foals infected with *Parascaris equorum* apparently resistant to ivermectin. *J Am Vet Med Assoc* 2003;223:482–485.